

ORIGINAL ARTICLE

White and Gray Matter Abnormalities in Australian Footballers With a History of Sports-Related Concussion: An MRI Study

Brendan Major^{1,†}, Georgia F. Symons^{1,†}, Ben Sinclair^{1,2}, William T. O'Brien¹, Daniel Costello³, David K. Wright¹, Meaghan Clough¹, Steven Mutimer¹, Mujun Sun¹, Glenn R. Yamakawa¹, Rhys D. Brady^{1,3}, Michael J. O'Sullivan⁴, Richelle Mychasiuk¹, Stuart J. McDonald^{1,5}, Terence J. O'Brien^{1,2,3}, Meng Law^{1,6,7}, Scott Kolbe^{1,‡} and Sandy R. Shultz^{1,2,3,‡}

¹Department of Neuroscience, Monash University, Melbourne, VIC 3004, Australia, ²Department of Neurology, Alfred Health, Melbourne, VIC 3004, Australia, ³Department of Medicine, The University of Melbourne, Parkville, VIC 3050, Australia, ⁴Department of Faculty of Medicine, UQ Centre for Clinical Research and Institute of Molecular Bioscience, The University of Queensland, Brisbane, QLD 4072, Australia, ⁵Department of Physiology, Anatomy, and Microbiology, La Trobe University, Melbourne, VIC 3086, Australia, ⁶Department of Radiology, Alfred Health, Melbourne, VIC 3004, Australia and ⁷Department of Electrical and Computer Systems Engineering, Monash University, Melbourne, VIC 3800, Australia

Address correspondence to Associate Professor Sandy Shultz, Department of Neuroscience, Monash University, 6th Floor, The Alfred Centre, 99 Commercial Road, Melbourne, VIC 3004, Australia. Email: sandy.shultz@monash.edu.

[†]Brendan Major and Georgia F. Symons are equal first authors.

[‡]Scott Kolbe and Sandy R. Shultz are equal senior authors.

Abstract

Sports-related concussion (SRC) is a form of mild traumatic brain injury that has been linked to long-term neurological abnormalities. Australian rules football is a collision sport with wide national participation and is growing in popularity worldwide. However, the chronic neurological consequences of SRC in Australian footballers remain poorly understood. This study investigated the presence of brain abnormalities in Australian footballers with a history of sports-related concussion (HoC) using multimodal MRI. Male Australian footballers with HoC ($n = 26$), as well as noncollision sport athletes with no HoC ($n = 27$), were recruited to the study. None of the footballers had sustained a concussion in the preceding 6 months, and all players were asymptomatic. Data were acquired using a 3T MRI scanner. White matter integrity was assessed using diffusion tensor imaging. Cortical thickness, subcortical volumes, and cavum septum pellucidum (CSP) were analyzed using structural MRI. Australian footballers had evidence of widespread microstructural white matter damage and cortical thinning. No significant differences were found regarding subcortical volumes or CSP. These novel findings provide evidence of persisting white and gray matter abnormalities in Australian footballers with HoC, and raise concerns related to the long-term neurological health of these athletes.

Key words: biomarker, cavum septum pellucidum, diffusion weighted imaging, mild traumatic brain injury, neuroimaging

Introduction

Sports-related concussion (SRC) is a form of mild traumatic brain injury (mTBI) particularly common in collision sport athletes (Symons, Clough, Fielding, et al. 2020a). There is growing evidence that a history of SRC (HoC) is linked to long-term neurological abnormalities, including microstructural white matter damage (Wallace et al. 2018; Zhang et al. 2019; Wright, Gardner, et al. 2021a). For example, diffusion tensor MRI (DTI) studies have found that white matter tracts in individuals with HoC have decreased fractional anisotropy (FA) and increased mean diffusivity (MD) (Zhang et al. 2019). Furthermore, a meta-analysis of 44 DTI studies found that this white matter damage was often widespread, affecting a range of structures in both the acute and chronic stages of mTBI (Wallace et al. 2018). Similar results were also reported in a cohort of retired Australian rugby players with HoC (Wright, Gardner, et al. 2021a). In addition to these white matter irregularities, studies have also identified abnormalities linked to HoC in other brain structures (Wojtowicz et al. 2018; Bernick et al. 2020; Mills et al. 2020; Wright, Gardner, et al. 2021a) including reduced volume of subcortical structures (e.g., hippocampi and amygdala; Strain et al. 2015; Wojtowicz et al. 2018) and cortical thinning (Patel et al. 2020). An increased incidence of cavum septum pellucidum (CSP), a possible marker of brain injury, has also been found in athletes with HoC (Gardner et al. 2016).

Australian football is an Australia's most participated collision sport (~1.5 million people annually; Costello et al. 2018; Symons, Clough, Fielding, et al. 2020a) and has an estimated incidence of 2.2–17.5 SRCs/1000 playing hours (McNeel et al. 2020). Despite its popularity, relatively few studies have investigated the neurological impact of HoC in Australian footballers (Symons, Clough, Fielding, et al. 2020a). Rather, the majority of previous research investigating the consequences of HoC has been conducted in popular North American and European sports such as American football, ice hockey, and soccer (Costello et al. 2018; Symons, Clough, Fielding, et al. 2020a), and has primarily involved older and/or retired athletes (Alosco et al. 2020; Hart et al. 2013; Strain et al. 2013). Unlike American football and ice hockey, Australian football is played without helmets, which may modify the nature of injury compared to helmeted sports (McIntosh et al. 2014). Therefore, the present study applied multimodal MRI to examine white and gray matter integrity in current Australian footballers with HoC compared to control noncollision sport athletes with no HoC. It was hypothesized that Australian footballers with HoC would have reduced white matter integrity, cortical thinning, reduced subcortical volumes, and increased prevalence and severity of CSP compared to the noncollision sport athletes with no HoC.

Materials and Methods

Participants

A total of 26 male Australian football players with a self-reported history of clinically diagnosed SRC sustained during Australian football participation were recruited from the Victorian Amateur Football Association. A control group of 27 athletes of similar age and education (see Table 1) with no HoC and no previous engagement in collision sports (i.e., sports that permit intentional tackling and/or forceful collisions) were also recruited from local amateur teams/clubs (field hockey, rowing, basketball, and track). To minimize the confounding effects of recent concussive and subconcussive injury, Australian

footballers who had sustained a concussion in the past 6 months were not enrolled into the study, and all data collection was performed at the onset of preseason training before any competitive matches (i.e., largely aerobic training activities). Individuals with a history of neurosurgery, nonsport-related brain injury, or previously diagnosed major psychiatric disorders were excluded. The Melbourne Health Human Ethics committee (#2015.012) approved study procedures, and all participants provided the written informed consent. We previously published preliminary MRI results in a subset of participants ($n = 15/\text{group}$) in a paper focused on ocular motor assessment in Australian footballers with HoC compared to controls (Clough et al. 2018). These preliminary MRI findings did not identify statistically significant differences between the groups; however, this analysis was admittedly underpowered to do so. Therefore, this study is a continuation of that preliminary data with an additional 23 participants (11 HoC, 12 Control).

Demographics and HoC

A questionnaire was administered by a trained research assistant to each participant pertaining to demographics, HoC, sporting history, education history, as well as any learning difficulties.

MRI Acquisition

MRI acquisition was performed on a 3T scanner (Magnetom Prisma; Siemens, Erlangen, Germany). MRI scanning was performed during the preseason training period prior to the first competitive game. Data collection included diffusion weighted imaging (DWI) to assess DTI measures of white matter integrity, as well as T1-weighted anatomical images for volumetric, cortical thickness, and CSP analyses. T1-weighted images were acquired using a three-dimensional magnetization prepared rapid gradient echo (MP-RAGE) sequence with the following parameters: repetition time (TR) = 2400 ms; echo time (TE) = 2.24 ms; inversion time = 1060 ms; flip angle = 8°; field of view (FOV) = 256 · 256 mm²; 192 slices with thickness = 0.8 mm; resolution = 0.8 · 0.8 · 0.8 mm³; and total acquisition time = 6 min 38 s. DWI was acquired at 2-mm isotropic resolution over 64 directions at $b = 3000 \text{ s/mm}^2$. Imaging was performed with a repetition time = 3400 ms; TE = 79 ms; FOV = 25.6 × 25.6 mm²; and acquisition matrix = 128 × 128. A reverse phase-encode image was also acquired to correct for distortions due to B₀-field inhomogeneity.

DTI Analysis

Preprocessing was performed using MRtrix3 and FSL, and included denoising followed by motion and distortion correction. Images were subsequently corrected for B₁ inhomogeneity using the N4 algorithm (included as part of ANTS). Global intensity normalization was performed using a white matter mask, and DW images were upsampled to 1.3-mm isotropic resolution. An unbiased study-specific template was built using 40 datasets (20 HoC/20 control) using MRtrix's multiresolution population atlas procedure using 5 iterations per scale level. DTI metrics including FA, radial diffusivity (RD), axial diffusivity (AD), and apparent diffusion coefficient (ADC) were calculated using MRtrix3 and nonlinearly aligned to template space for analysis with FSL's tract-based spatial statistics (TBSS; Smith et al. 2006; Wright, Gardner, et al. 2021a). Statistical significance was determined for each voxel on the white matter skeleton based

Table 1 Demographics and HoC information (mean \pm SE)

	Controls	HoC	P value (t-test)
N	27	26	
Age	23.74 (0.45)	24.42 (0.60)	0.366
Years of education	16.27 (0.24)	16.19 (0.39)	0.868
Height (cm)	182.00 (2.14)	181.44 (1.33)	0.820
Weight (kg)	77.92 (3.92)	80.06 (1.48)	0.618
Age commenced sport	7.11 (0.65)	6.33 (0.49)	0.361
Years sport played	15.67 (0.97)	18.17 (0.90)	0.099
Age commenced collision sport	—	8.55 (0.58)	—
Years played collision sports	—	15.56 (1.09)	—
Total no. previous concussion	—	2.54 (0.30)	—

on nonparametric permutation testing (5000 permutations) and threshold free cluster enhancement (TFCE).

Cortical Thickness and Subcortical Volumes

Volumetric analysis of cortical and subcortical brain structures was performed using FreeSurfer (version 6.0-patch) according to the standard anatomical processing pipeline: removal of non-brain tissue, automated Talairach transformation, segmenting of subcortical white matter and deep gray matter structures, intensity normalization, gray matter/white matter boundary tessellation, automated topology correction, and surface deformation following intensity gradients along the gray/white and gray/CSF borders (Dale et al. 1999; Fischl et al. 2001; Fischl et al. 2002).

Volumes of subcortical structures were expressed as a percentage of total intracranial volume. In line with previous SRC investigations (Wojtowicz et al. 2018; Bernick et al. 2020), region of interest analysis was performed on the hippocampus, thalamus, and amygdala of both the right and left hemispheres.

Cortical thickness was analyzed using vertex-wise general linear models in QDEC. Briefly, vertex-wise thickness estimates for each subject were resampled to the fsaverage cortical template and smoothed with a 10-mm full-width half maximum Gaussian filter. General linear models tested for the main effect of concussion group, while correcting for nuisance variables (age, years of play). Cluster-based thresholding was used to control for family-wise error using Monte Carlo simulation thresholded at $P < 0.05$ using the method described previously (Hagler et al. 2006).

CSP Measures

The characterization of CSP was assessed using the T1-weighted images and performed as previously described (Clough et al. 2018). CSP was defined as cerebrospinal fluid (CSF) being visible between two leaflets of the septi pellucidi on the coronal slices (Koerte et al. 2016; Clough et al. 2018). Two characterization methods were included in this study, CSP grade and length, as described below.

CSP grade was determined in the coronal slice based on the greatest evidence of cavity. CSP grades ranged between 0 (absent), 1 (questionable), 2 (mild), 3 (moderate), and 4 (severe) (Clough et al. 2018). A grade of 0 or 1, was considered as no CSP present and a grade of 2–4 was considered as a clear presence of CSP with varying degrees of severity. The same observer (GFS), blind to participant group, graded all scans. A second blinded observer (BM) graded CSP's and inter-rater reliability

was determined as 0.874. Any disagreement or discordance was resolved with a third blinded observer who is an experienced board certified neuroradiologist (ML).

CSP length was determined in the coronal view, and anterior-posterior length of the CSP was measured by the number of contiguous slices containing evidence of the CSP. Length (mm) was determined as the number of slices multiplied by 0.8 mm (slice thickness). As above the same observer (GFS), blind to participant group, determined CSP length. This was confirmed by a second blinded observer (BM) and inter-rater reliability was determined as 0.945.

Statistical Analysis

SPSS software (version 22.0; IBM Corp., Armonk, NY) was used for all statistical analyses with the exception of the TBSS and QDEC analyses described above. Between groups, differences on the demographic variables, subcortical volumes, and CSP length were analyzed with independent t-tests. Chi-square tests were used to assess differences between groups in the prevalence and grade of CSP. Statistical significance for all analyses was set at $P < 0.05$. For subcortical volumes, multiple comparisons were accounted for using Benjamini and Hockberg's False Discovery Rate (FDR), with an FDR value of less than 5% considered significant. For cortical thickness, group comparisons were performed with age and years of play as covariates. Results are presented as mean \pm SE.

Results

Demographics and HoC

Demographic, sporting history, and HoC findings are presented in Table 1. No significant differences were found on any demographic measures between the groups.

White Matter Microstructure

TBSS analysis of DTI metrics found significant ($P_{TFCE} < 0.05$) decreases in FA, and significant increases in RD, throughout major white matter tracts (e.g., superior longitudinal fasciculus, SLF; corpus collosum, CC; and corticospinal tract, CST) in the Australian footballers relative to the noncollision sport athletes with no HoC (Fig. 1). There were no statistically significant differences between the groups on the measures of AD or ADC.

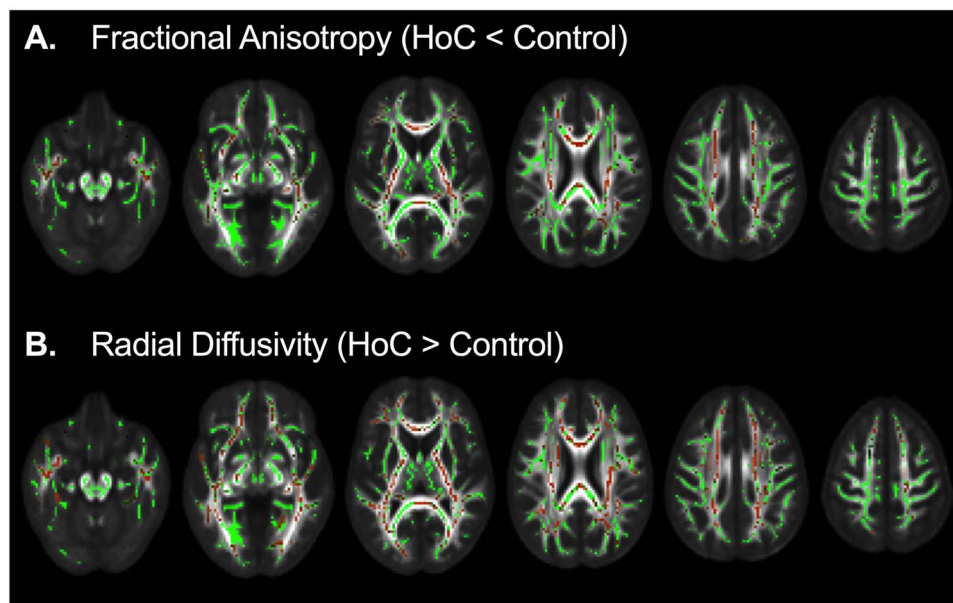


Figure 1. TBSS of diffusion tensor imaging measures. Australian footballers with a history of concussion had significantly decreased fractional anisotropy (A) and increased radial diffusivity (B) in white matter tracts, including the superior longitudinal fasciculus, corpus callosum, and corticospinal tract, compared to noncollision sport control athletes with no history of concussion. Regions that are statistically different between the groups are illustrated in red ($P_{TFCE} < 0.05$). The TBSS white matter skeleton is illustrated in green. These have been overlaid on average fractional anisotropy map templates (grey scale).

Table 2 Subcortical findings (cm³; mean \pm SE)

	Controls	HoC	P value
N	27	26	
Thalamus: left	8.66 (0.14)	8.66 (0.14)	0.53
Thalamus: right	8.45 (0.14)	8.42 (.014)	0.16
Hippocampus: left	3.73 (.13)	3.76 (.11)	0.71
Hippocampus: right	3.84 (.09)	3.88 (0.12)	0.45
Amygdala: left	1.34 (0.04)	1.40 (.06)	0.34
Amygdala: right	1.4 (.06)	1.48 (.05)	0.32

Cortical Thinning and Volumetric Analyses

QDEC analysis revealed statistically significant cortical thinning in the frontal, insula, and temporal regions of the right hemisphere, as well as frontal cortex and cingulate of the left hemisphere of the Australian footballers compared with controls (Fig. 2).

Results of between-group analysis of subcortical regions are presented in Table 2. No significant group differences were found for any of the subcortical regions examined.

Cavum Septum Pellucidum

The presence and length of CSP between groups is summarized in Table 3. No significant group differences were found on any CSP measures ($P > 0.05$).

Discussion

This study used multimodal MRI to examine for micro- and macrostructural brain abnormalities in Australian footballers with a remote HoC (i.e., no concussion in at least 6 months before study onset) compared to control athletes with no HoC.

In support of our hypothesis, we found widespread evidence of alterations in white matter microstructure in the CC, SFL, and CST of the Australian footballers. There was also evidence of subtle cortical thinning in both the right and left hemispheres. There were no differences between the groups on measures of subcortical brain structure volumes or the prevalence and severity of CSP.

We previously conducted a preliminary multimodal MRI analysis, including DTI and CSP, in a subset of the current cohort that did not identify statistically significant differences in Australian footballers with HoC compared to controls (Clough et al. 2018). The primary outcome in that study was cognitive ocular motor function and was explicitly stated in that paper, the MRI analysis was underpowered and required additional participants. The current study is, therefore, an extension of that preliminary analysis with an additional 23 participants included to reach adequate group sizes.

The present finding of decreased FA in major white matter tracts is generally consistent with previous SRC (e.g., ice hockey, American football, rugby) and mTBI literature (Tremblay et al. 2014; Wallace et al. 2018; Zhang et al. 2019; Wright, Gardner, et al. 2021a). The location of these abnormalities (i.e., SLF, CST, and CC) also aligns with past findings in the context of HoC in American football, ice hockey, and rugby (Henry et al. 2011; Koerte et al. 2012; Lancaster et al. 2018; Wright, Gardner, et al. 2021a). Notably, there is a commonality in the physical properties of the affected areas, with each comprised of long-range fibers. Despite different modes of injury across studies (e.g., sports, motor vehicle accidents, military injuries), these common abnormalities found in long-range white matter fibers suggest a point of vulnerability in the brain to mTBI. It remains unclear whether it is the location of these structures (e.g., near the center of mass) or physical properties (e.g., long axons) that make them so susceptible to the shear and strain forces induced in mTBI (Arbogast and Margulies 1998). In vivo investigations into forces (both shear and strain)

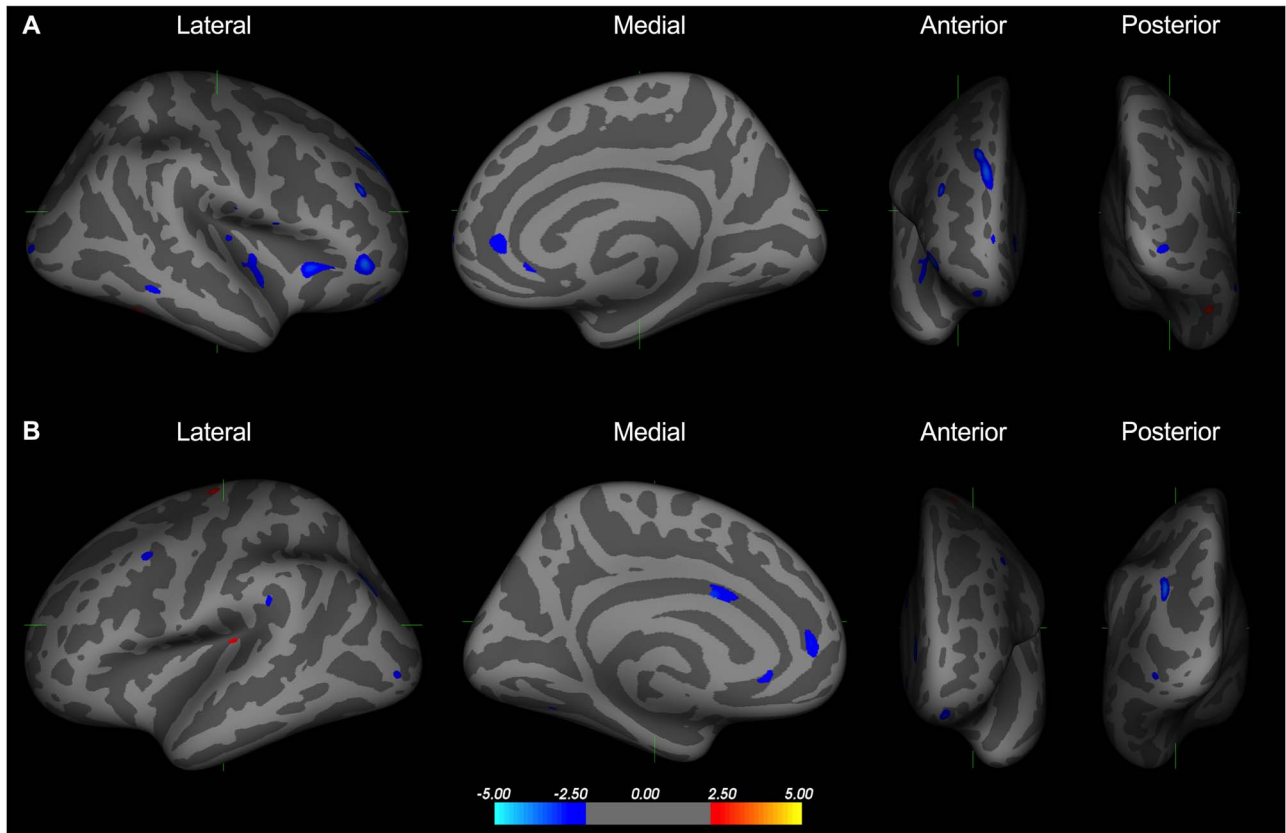


Figure 2. Areas of cortical thinning in Australian footballers with a history of concussion. Australian footballers with a history of concussion had cortical thinning in the frontal, insula, and temporal regions of the right hemisphere (A), as well as in the frontal cortex and cingulate of the left hemisphere (B) relative to noncollision sport control athletes with no history of concussion. Blue = Australian footballers < controls; red indicates Australian footballers > controls; $P < 0.05$.

Table 3 CSP findings

CSP grade	Controls (n = 27)		HoC (n = 26)		Analysis	
	N	%	N	%	X2	P
0	3	11.1	2	7.7		
1	16	59.3	10	38.5		
2	7	25.9	9	34.6		
3	0	0.0	5	19.2		
4	1	3.7	0	0.0		
Prevalence of CSP	N = 8		N = 14		3.199	0.098
Length (mm)	Mean	S.E.	Mean	S.E.		P
	4.60	2.670	4.29	2.00		0.758

exerted on the brain during mTBI, corroborate our findings, and demonstrate particular areas of vulnerability (Hirad et al. 2019). Namely, the areas identified in the current study, including the frontal lobes, brainstem, and tracts that border the gray matter, may experience high tension, even with minimal rotational motion.

Considering the remote (>6 months) nature of past concussions in the current investigation, our evidence suggests that HoC is associated with either persistent or delayed microstructural abnormalities in white matter. It is inherently difficult to determine the exact progression and pathology underlying DTI changes in clinical HoC studies. Previous studies suggest that changes in DTI metrics may reflect disruptions of the

axonal structure (Arfanakis et al. 2002), Wallerian degeneration (Pierpaoli et al. 2001), axonal degeneration (Song et al. 2003), demyelination (Song et al. 2002), edema (MacDonald et al. 2007), or gliosis (Budde et al. 2011). Such pathologies could be induced by the biomechanical forces at the time of impact, and/or via secondary injury pathways such as oxidative stress and inflammation. For example, a recent study from our group found that Australian footballers had diffusion MRI abnormalities acutely after SRC that were still present at 2 weeks postinjury (i.e., the final recovery time they were scanned; Wright, Symons, et al. 2021b). Furthermore, we also found that serum levels of neurofilament light, a protein abundant in myelinated axons, continued to rise for at least 2 weeks after SRC (McDonald et al.

2021). These findings suggest that the immediate consequences of SRC can persist for at least several weeks and could potentially result in chronic changes. We have also investigated circulating protein biomarkers associated with oxidative stress and inflammation in separate cohorts of Australian footballers with a remote HoC (Major et al. 2020; O'Brien et al. 2020; Symons, Clough, O'Brien, et al. 2020b). Overall, these studies have found evidence of both increased inflammation and oxidative stress (i.e., secondary injury mechanisms) in Australian footballers (Major et al. 2020; O'Brien et al. 2020; Symons, Clough, O'Brien, et al. 2020b). Notably, these findings occurred in the presence of increased levels of blood biomarkers indicative of axonal injury and neurodegeneration (i.e., tau and phosphorylated tau; Symons, Clough, O'Brien, et al. 2020b). Preclinical findings in rats also link persisting neuroinflammation and oxidative stress to white and gray matter damage after mTBI (Shultz et al. 2012; Shultz et al. 2013; Webster et al. 2015). Taken together, these findings support the notion that both the primary impact as well as secondary injury pathways may have mechanistic roles in long-term brain damage after mTBI.

Our study also found evidence of subtle cortical thinning, primarily in the frontal areas, of the HoC athletes compared to controls. This aligns with previous work reporting cortical thinning in former collision sport athletes (Meier et al. 2016). There were no other overt morphological changes within the HoC athletes (i.e., subcortical volumes or CSP). A possible explanation for the lack of more robust morphological findings is the relatively young age of these participants not affording secondary injury processes enough time to manifest into subcortical changes, compared to previously studied retired American football (Strain et al. 2015) and rugby players (Wojtowicz et al. 2018) of more advanced years. Currently, there is conflicting evidence regarding cortical changes following mTBI. While there is evidence supporting a reduction in cortical volume in mTBI participants when compared with healthy controls (Meier et al. 2016), recent work has also indicated an increase in cortical thickness in HoC athletes compared to healthy controls (Mills et al. 2020). The mode of injury, exposure, and age are all factors that might contribute to these variable findings and should be examined further.

With regards to the CSP findings, again, age, and exposure are two possible explanations for our nonsignificant results. For example, previous studies that have reported CSP abnormalities in American football players with HoC have been conducted in substantially older cohorts of symptomatic retired athletes (Gardner et al. 2016; Koerte et al. 2016), as well as in boxers with a more extensive HoC (Ng et al. 2014). The exact mechanisms responsible for CSP after neurotrauma remain to be elucidated, but might involve shearing forces causing immediate fenestration and/or a more progressive formation due to secondary injury, cerebral atrophy, and ventricular dilation. It should also be noted that CSP is not specific to neurotrauma and has been linked to neurodevelopmental and genetic conditions (Shenton et al. 2001; Beaton et al. 2010; Hwang et al. 2013). The reported prevalence of CSP in the general population (Born et al. 2004; Gur et al. 2013), as well as control athletes with no HoC (e.g., >50% in Koerte et al. 2016), also varies greatly.

This study had several limitations that should be considered when interpreting the results. Our study was limited to male participants, and future studies should include females particularly in light of evidence indicating that biological sex might influence the pathobiology of mTBI (Colantonio 2016). Notably, Australian football may provide the ideal sport for such

studies given the similar full-contact rules in both men and women leagues (Symons, Clough, Fielding, et al. 2020a). Our study also focused on relatively young-adult athletes, and it would be of interest to follow these athletes longitudinally to investigate whether the observed abnormalities worsen, recover, or plateau with age. HoC was self-reported, and details related to the criteria used for clinical diagnosis and the exact timing of the injuries (apart from not occurring in the past 6 months) were not available for all participants, which could impact the accuracy of this measure. Previous studies have also reported neurological consequences of participating in collision sports independent of HoC (Manning et al. 2020). However, because our study focused on Australian footballers with HoC, and did not include an Australian football group with no HoC for comparison, we are unable to ascertain whether the findings are specific to those with HoC. For example, the observed differences may be due to subconcussive impacts irrespective of HoC. It is also possible that individuals who choose to participate in Australian football have inherent neurological differences compared to athletes participating in noncollision sports. Lastly, other neuroimaging modalities such as magnetic resonance spectroscopy, arterial spin labeling, or positron emission tomography (Gorgoraptis et al. 2019; Symons, Clough, Fielding, et al. 2020a) could be applied in future studies to investigate whether metabolic, cerebrovascular, or other molecular abnormalities are also present in Australian footballers with HoC.

In conclusion, this multimodal MRI study found evidence of persisting white and gray matter damage in young-adult Australian footballers with HoC in comparison with control athletes with no HoC. Despite the abovementioned limitations and the need for further studies, this is the first study to report chronic macro- and microstructural brain abnormalities in young-adult Australian footballers with HoC and raises concerns related to the long-term neurological health of these athletes.

Funding

Australian National Health and Research Council (to S.R.C., R.M., and S.J.M.).

Notes

Conflict of Interest: The authors have no conflict of interest to declare.

References

- Alosco ML, Tripodis Y, Rowland B, Chua AS, Liao H, Martin B, et al. 2020. A magnetic resonance spectroscopy investigation in symptomatic former NFL players. *Brain Imaging Behav.* 14(5):1419–1429.
- Arbogast KB, Margulies SS. 1998. Material characterization of the brainstem from oscillatory shear tests. *J Biomech.* 31:801–807.
- Arfanakis K, Houghton VM, Carew JD, Rogers BP, Dempsey RJ, Meyerand ME. 2002. Diffusion tensor MR imaging in diffuse axonal injury. *Am J Neuroradiol.* 23:794–802.
- Beaton EA, Qin Y, Nguyen V, Johnson J, Pinter JD, Simon TJ. 2010. Increased incidence and size of cavum septum pellucidum in children with chromosome 22q11.2 deletion syndrome. *Psychiatry Res.* 181:108–113.
- Bernick C, Shan G, Zetterberg H, Banks S, Mishra VR, Bekris L, et al. 2020. Longitudinal change in regional brain volumes with exposure to repetitive head impacts. *Neurology.* 94:e232–e240.

- Born CM, Meisenzahl EM, Frodl T, Pfluger T, Reiser M, Moller HJ, et al. 2004. The septum pellucidum and its variants: an MRI study. *Eur Arch Psychiatry Clin Neurosci.* 254:295–302.
- Budde MD, Janes L, Gold E, Turtzo LC, Frank JA. 2011. The contribution of gliosis to diffusion tensor anisotropy and tractography following traumatic brain injury: validation in the rat using Fourier analysis of stained tissue sections. *Brain.* 134:2248–2260.
- Clough M, Mutimer S, Wright DK, Tsang A, Costello DM, Gardner AJ, et al. 2018. Oculomotor cognitive control abnormalities in Australian rules football players with a history of concussion. *J Neurotrauma.* 35:730–738.
- Colantonio A. 2016. Sex, gender, and traumatic brain injury: a commentary. *Arch Phys Med Rehabil.* 97:S1–S4.
- Costello DM, Ernest J, Kaye AH, O'Brien TJ, Shultz SR. 2018. Concussion incidence in amateur Australian rules footballers. *J Clin Neurosci.* 56:88–89.
- Dale AM, Fischl B, Sereno MI. 1999. Cortical surface-based analysis. *Neuroimage.* 9:179–194.
- Hagler DJ, Saygin AP, Sereno MI. 2006. Smoothing and cluster thresholding for cortical surface-based group analysis of fMRI data. *Neuroimage.* 33:1093–1103.
- Hart J, Kraut MA, Womack KB, Strain J, Didehbani N, Bartz E, et al. 2013. Neuroimaging of cognitive dysfunction and depression in aging retired national football league players. *JAMA Neurol.* 70(3):326.
- Fischl B, Liu A, Dale AM. 2001. Automated manifold surgery: constructing geometrically accurate and topologically correct models of the human cerebral cortex. *IEEE Trans Med Imaging.* 20:70–80.
- Fischl B, Salat DH, Busa E, Albert M, Dieterich M, Haselgrove C, et al. 2002. Whole brain segmentation: automated labeling of neuroanatomical structures in the human brain. *Neuron.* 33:341–355.
- Gardner RC, Hess CP, Brus-Ramer M, Possin KL, Cohn-Sheehy BI, Kramer JH, et al. 2016. Cavum septum pellucidum in retired American pro-football players. *J Neurotrauma.* 33:157–161.
- Gorgoraptis N, Li LM, Whittington A, Zimmerman KA, Maclean LM, McLeod C, et al. 2019. In vivo detection of cerebral tau pathology in long-term survivors of traumatic brain injury. *Sci Transl Med.* 11:eaaw1993.
- Gur RE, Kaltman D, Melhem ER, Ruparel K, Prabhakaran K, Riley M, et al. 2013. Incidental findings in youths volunteering for brain MRI research. *AJNR Am J Neuroradiol.* 34:2021–2025.
- Henry LC, Tremblay J, Tremblay S, Lee A, Brun C, Lepore N, et al. 2011. Acute and chronic changes in diffusivity measures after sports concussion. *J Neurotrauma.* 28:2049–2059.
- Hirad AA, Bazarian JJ, Merchant-Borna K, Garcea FE, Heilbronner S, Paul D, et al. 2019. A common neural signature of brain injury in concussion and subconcussion. *Sci Adv.* 5:eaau3460.
- Hwang J, Kim JE, Kaufmann MJ, Renshaw PF, Yoon S, Yurgelun-Todd DA, et al. 2013. Enlarged cavum septum pellucidum as a neurodevelopmental marker in adolescent-onset opiate dependence. *PLoS One.* 8:e78590.
- Koerte IK, Kaufmann D, Hartl E, Bouix S, Pasternak O, Kubicki M, et al. 2012. A prospective study of physician-observed concussion during a varsity university hockey season: white matter integrity in ice hockey players. *Neurosurg Focus.* 33:1–7.
- Koerte IK, Hufschmidt J, Muehlmann M, Tripodis Y, Stamm JM, Pasternak O, et al. 2016. Cavum septi pellucidi in symptomatic former professional football players. *J Neurotrauma.* 33:346–353.
- Lancaster MA, Meier TB, Olson DV, McCrea MA, Nelson LD, Muf-tuler LT. 2018. Chronic differences in white matter integrity following sport-related concussion as measured by diffusion MRI: 6-month follow-up. *Hum Brain Mapp.* 39:4276–4289.
- MacDonald CL, Dikranian K, Bayly P, Holtzman D, Brody D. 2007. Diffusion tensor imaging reliably detects experimental traumatic axonal injury and indicates approximate time of injury. *J Neurosci.* 27:11869–11876.
- Major BP, McDonald SJ, O'Brien WT, Symons GF, Clough M, Costello D, et al. 2020. Serum protein biomarker findings reflective of oxidative stress and vascular abnormalities in male, but not female, collision sport athletes. *Front Neurol.* 11:549624.
- Manning KY, Brooks JS, Dickey JP, Harriss A, Fischer L, Jevremovic T, et al. 2020. Longitudinal changes of brain microstructure and function in nonconcussed female rugby players. *Neurology.* 95:e402–e412.
- McDonald SJ, WT B'O, Symons GF, Chen Z, Bain J, Major BP, et al. 2021. Prolonged elevation of serum neurofilament light after concussion in male Australian football players. *Biomark Res.* 9:4.
- McIntosh AS, Patton DA, Fréchède B, Pierré P-A, Ferry E, Barthels T. 2014. The biomechanics of concussion in unhelmeted football players in Australia: a case-control study. *BMJ Open.* 4(5):e005078.
- McNeel C, Clark GM, Davies CB, Major BP, Lum JAG. 2020. Concussion incidence and time-loss in Australian football: a systematic review. *J Sci Med Sport.* 23:125–133.
- Meier TB, Bellgowan PSF, Bergamino M, Ling JM, Mayer AR. 2016. Thinner cortex in collegiate football players with, but not without, a self-reported history of concussion. *J Neurotrauma.* 33:330–338.
- Mills BD, Goubran M, Parivash SN, Dennis EL, Rezaii P, Akers C, et al. 2020. Longitudinal alteration of cortical thickness and volume in high-impact sports. *Neuroimage.* 217:116864.
- Ng TSC, Lin AP, Koerte IK, Pasternak O, Liao H, Merugumala S, et al. 2014. Neuroimaging in repetitive brain trauma. *Alzheimer's Res Ther.* 6:10.
- O'Brien WT, Symons GF, Bain J, Major BP, Costello DM, Sun M, et al. 2020. Elevated serum interleukin-1 β levels in male, but not female, collision sport athletes with a concussion history. *J Neurotrauma.* epub ahead of print.
- Patel JB, Wilson SH, Oakes TR, Santhanam P, Weaver LK. 2020. Structural and volumetric brain MRI findings in mild traumatic brain injury. *Am J Neuroradiol.* 41:92–99.
- Pierpaoli C, Barnett A, Pajevic S, Chen R, Penix LR, Virta A, et al. 2001. Water diffusion changes in wallerian degeneration and their dependence on white matter architecture. *Neuroimage.* 13:1174–1185.
- Strain J, Didehbani N, Cullum CM, Mansinghani S, Conover H, Kraut MA, et al. 2013. Depressive symptoms and white matter dysfunction in retired NFL players with concussion history. *Neurology.* 81(1):25–32.
- Shenton ME, Dickey CC, Frumin M, McDarley RW. 2001. A review of MRI findings in schizophrenia. *Schizophr Res.* 49:1–52.
- Shultz SR, Boa F, Omana V, Chiu C, Brown A, Cain DP. 2012. Repeated mild lateral fluid percussion brain injury in the rat causes cumulative long-term behavioral impairments, neuroinflammation, and cortical loss in an animal model of repeated concussion. *J Neurotrauma.* 29:281–294.
- Shultz SR, Bao F, Weaver LC, Cain DP, Brown A. 2013. Treatment with an anti-CD11d integrin antibody reduces

- neuroinflammation and improves outcome in a rat model of repeated concussion. *J Neuroinflammation*. 10:26.
- Smith SM, Jenkinson M, Johansen-Berg H, Rueckert D, Nichols TE, Mackay CE, et al. 2006. Tract-based spatial statistics: voxelwise analysis of multi-subject diffusion data. *Neuro Image*. 31:1487–1505.
- Song SK, Sun SW, Ramsbottom MJ, Chang C, Russell J, Cross AH. 2002. Dysmyelination revealed through MRI as increased radial (but unchanged axial) diffusion of water. *Neuroimage*. 17:1429–1436.
- Song SK, Sun SW, Ju WK, Lin SJ, Cross AH, Neufeld AH. 2003. Diffusion tensor imaging detects and differentiates axon and myelin degeneration in mouse optic nerve after retinal ischemia. *Neuroimage*. 20:1714–1722.
- Strain JF, Womack KB, Didehbani N, Spence JS, Conover H, Hart J, et al. 2015. Imaging correlates of memory and concussion history in retired National Football League athletes. *JAMA Neurol*. 72:773–780.
- Symons GF, Clough M, Fielding J, O'Brien WT, Shepherd CE, Wright DK, et al. 2020a. The neurological consequences of engaging in Australian collision sports. *J Neurotrauma*. 809:792–809.
- Symons GF, Clough M, O'Brien WT, Ernest J, Salberg S, Costello D, et al. 2020b. Shortened telomeres and serum protein biomarker abnormalities in collision sport athletes regardless of concussion history and sex. *J Concussion*. 4. <https://doi.org/10.1177/2059700220975609>.
- Tremblay S, Henry LC, Bedetti C, Larson-Dupuis C, Gagnon JF, Evans AC, et al. 2014. Diffuse white matter tract abnormalities in clinically normal ageing retired athletes with a history of sports-related concussions. *Brain*. 137:2997–3011.
- Wallace EJ, Mathias JL, Ward L. 2018. Diffusion tensor imaging changes following mild, moderate and severe adult traumatic brain injury: a meta-analysis. *Brain Imaging Behav*. 12:1607–1621.
- Webster KM, Wright DK, Sun M, Semple BD, Ozturk E, Stein DG, et al. 2015. Progesterone treatment reduces neuroinflammation, oxidative stress and brain damage and improves long-term outcomes in a rat model of repeated mild traumatic brain injury. *J Neuroinflammation*. 12:238.
- Wojtowicz M, Gardner AJ, Stanwell P, Zafonte R, Dickerson BC, Iverson GL. 2018. Cortical thickness and subcortical brain volumes in professional rugby league players. *NeuroImage Clin*. 18:377–381.
- Wright DK, Gardner AJ, Wojtowicz M, Iverson GL, O'Brien TJ, Shultz SR, et al. 2021a. White matter abnormalities in retired professional rugby league players with a history of concussion. *J Neurotrauma*. 38:983–988.
- Wright DK, Symons GF, O'Brien WT, McDonald SJ, Zamani A, Major B, et al. 2021b. Diffusion imaging reveals sex differences in the white matter following sports-related concussion. *Cereb Cortex*. Online ahead of print.
- Zhang J, Tian L, Zhang L, Cheng R, Wei R, He F, et al. 2019. Relationship between white matter integrity and post-traumatic cognitive deficits: a systematic review and meta-analysis. *J Neurol Neurosurg Psychiatry*. 90:98–107.